


# The Neurological Hand Deformity Classification (NHDC) Manual

Simon Garbellini – MHIthServMgt, BSc (OT)  
Judith Wilton – MSc, PGradDIP HthSc, BAppSc (OT)



Second Edition - 2 June 2020



Government of Western Australia  
Child and Adolescent Health Service





## Table of contents

Section	Content	Page
1.	The Neurological Hand Deformity Classification	3
	1.1 Introduction	3
	1.2 Purposes	3
	1.3 Background	4
	1.4 Psychometric properties	5
2.	Administration of the Neurological Hand Deformity Classification	6
	2.1 General instruction	6
	2.2 Real time classification or video recording	7
	2.3 Number of attempts	7
	2.4 Classification for young children	7
	2.5 Clients with limited or no active movement	7
3.	Set up	8
	3.1 Position of client	8
	3.2 Objects to elicit wrist and hand movement	8
	3.3 Position of object	9
	3.4 Position of camera	9
	3.5 Instructions	9
	3.6 Important points to remember	9
4.	Determining classification level	10
	4.1 Wrist movement	10
	4.2 Wrist position	10
	4.3 Finger movement	10
5.	Wrist and finger movement considerations of the Neurological Hand Deformity Classification	11
6.	Distinction between classification levels	12
7.	Clinical reporting	13
8.	Clinical application	14
9.	The Neurological Hand Deformity Classification (NHDC) (Wilton, 2013)	15
10.	Orthotic intervention considering hand deformity classification	16
11.	Orthosis considerations utilising the NHDC	17
	11.1 Clinical example	18
12.	Conclusion	18
13.	Authors	19
14.	Correspondence	19
15.	Acknowledgements	19
16.	References	20



# 1. The Neurological Hand Deformity Classification

## 1.1 Introduction

Active movement of the wrist and hand involves a complex interaction of intrinsic and extrinsic musculature. For people with neurologically-based impairment, an imbalance of muscle activity drives the pattern of wrist and hand deformity (Wilton, 2013). Even though impairment is unique to each individual, hand deformity tends to follow characteristic patterns (Wilton, 2003, 2013).

The primary purpose of any classification tool in health care is to discriminate between variations in the presentation of a health condition at a particular point in time (Kirshner & Guyatt, 1985; McConnell, Johnston, & Kerr, 2011; Rosenbaum, Eliasson, Hidecker, & Palisano, 2014; Rosenbaum et al., 1990). The Neurological Hand Deformity Classification (NHDC) is framed within the body functions and structure domain of the International Classification of Functioning Disability and Health (ICF) (World Health Organization, 2001). Thus, the NHDC is an impairment-based classification designed to categorise hand deformity. The NHDC was developed to classify deviation or loss of wrist and hand movement attributed to changes in body structure of the affected upper limb(s). It is designed for use with clients of any age across all neurologically-based upper limb impairments. The application of the NHDC is not limited to a specific diagnosis, but has been predominantly used by the authors in clinical practice with children and adults with cerebral palsy.

**Note that the NHDC is not an assessment of the details of hand function or even of impairment. Classification is made according to observed wrist and hand movement.** The NHDC consists of two extension categories (E1 and E2) and five flexion categories (F1 to F5). Differentiation between the categories is determined by wrist position and wrist and finger movement.

## 1.2 Purposes

The purposes of classifying hand deformity using the NHDC are:

- To facilitate observation and analysis of the anatomical and biomechanical components of neurologically-based wrist and hand deformity.
- To identify the primary factors causing the dynamic presentation of the deformity during active wrist and hand movement.
- To provide a framework for therapists to consider intervention options based upon the dynamic pattern of movement observed.

The NHDC is intended to categorise wrist and hand movement in action; assist identification of structures driving hand deformity; guide clinical assessment; and enhance clinical decision-making regarding the use of upper limb orthoses as part of the overall management of upper limb impairment.



## 1.3 Background

Classifications of patterns of wrist, finger and thumb deformities were originally developed by surgeons to select the most appropriate surgical intervention for individual patients (House, Gwathmey, & Fidler, 1981; Tonkin, Freitas, Koman, Leclercq, & Van Heest, 2008; Tonkin, Hatrick, Eckersley, & Couzens, 2001; Zancolli, 2003; Zancolli & Boyes, 1979; Zancolli, Goldner, & Swanson, 1983; Zancolli & Zancolli, 1981, 1984, 1987). Zancolli (2003) classified a child's 'spastic hand', into one of three groups, based upon observation of degree of wrist flexion required to produce voluntary release of the fingers. Flexion contracture of the wrist and or fingers is corrected through surgical techniques based on the classification level observed. House et al. (1981) developed a thumb deformity classification, with different static and dynamic components of thumb deformity described in four levels. Surgeries to address thumb deformities in different levels of the House classification included release of contractures, augmentation of weak muscles and skeletal stabilisation (House et al., 1981). However, since the function of the thumb is related to the position and stability of the wrist, the thumb deformity may be worsened when the wrist is placed in a more functional position (House et al., 1981). Therefore correction of thumb deformity must take into account deformity in the proximal joints, particularly the wrist (Tonkin et al., 2008).

Establishment of the validity and reliability of the Zancolli and House classifications was not undertaken by the authors of the classifications. Klingels et al. (2010) established inter-rater ( $=0.95$ ) and test-retest reliability ( $=1$ ) of the Zancolli classification, and inter-rater ( $= 0.73$ ) and test-retest reliability ( $= 0.74$ ) of the House classification, as part of a clinical test battery to assess upper limb impairment in children with hemiplegia.

Limitations were identified in the use of these surgical classifications to facilitate appropriate therapy treatment planning (Georgiades et al., 2014). The Zancolli classification is limited to patterns of wrist flexion deformity and does not include extension deformities, nor does it encourage the observer to consider the contributions of extrinsic and intrinsic finger and thumb musculature when describing deformity patterns. The House classification describes thumb deformity without reference to wrist position, whereas in surgical practice the wrist position and its impact on thumb deformity is considered prior to surgical intervention (House et al., 1981; Tonkin et al., 2008). A thorough search of the literature failed to yield instructions or guidelines for use of these classifications.

The Neurological Hand Deformity Classification (NHDC) was developed by Judith Wilton, occupational therapist, in recognition of limitations in the use of surgical classifications. The NHDC differs from these other classifications by observing dynamic movement of the whole hand and thumb, including flexion and extension deformities with concurrent thumb deformity. Clinical observations of consistent patterns of wrist and hand deformity during function in clinical practice (Georgiades et al., 2014; Wilton, 2003, 2013), the surgical classifications of spastic hand deformities in the wrist and fingers (Zancolli, 2003; Zancolli & Boyes, 1979; Zancolli et al., 1983; Zancolli & Zancolli, 1981, 1984, 1987) and patterns of thumb deformity (House et al., 1981) were utilised in the development of the NHDC.





## 1.4 Psychometric properties

The usefulness of measurement tools in decision making and clinical research depends on whether clinicians can rely on the generated information as accurate and meaningful (Portney & Watkins, 2015). Both reliability (the extent to which a tool is consistent and free from error) and validity (assuring the tool measures what it is intended to measure) are essential considerations when selecting a tool to use (Portney & Watkins, 2015). An initial reliability study of the NHDC has been published (Georgiades et al., 2014), and demonstrated high levels of both inter-observer and intra-observer reliability ( $=0.87$  and  $=0.91$  respectively). Further testing of the psychometric properties of the NHDC is currently being undertaken to provide additional evidence about construct validity, test-retest and inter-rater reliability.



Figure 1: Live classification of a client's right hand deformity using the NHDC.



## 2. Administration of the Neurological Hand Deformity Classification

### 2.1 General instruction

Classification of hand deformity is determined by **observing the client's wrist and hand in action** during movement towards and attempted grasp and release of objects as described in Section 4. The classification is based upon the **analysis of active wrist and finger movement in relation to the extended or flexed position of the wrist**. The extended or flexed wrist position is determined from a neutral ( $0^\circ$ ) wrist position as seen in Figure 1.

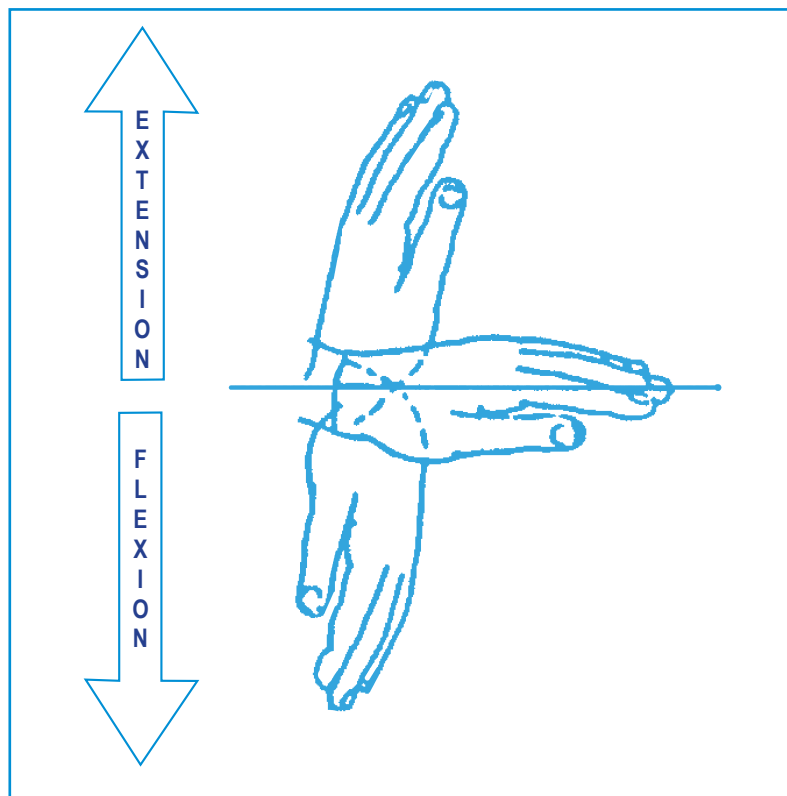


Figure 1: Guideline for wrist position

The pattern of wrist and hand movement is the focus of the classification regardless of success or the effectiveness of grasp and release. The procedure to classify hand deformity using the NHDC is the same in either a clinical or a research context.



## 2.2 Real time classification or video recording

Classification of hand deformity can be made either at the time of live clinical observation or completed at a later time from recorded footage. Regardless of the timing of classification, it is recommended that the client's wrist and hand movement be recorded. Footage of the individual client's wrist and hand movement allows comparison of the details of their movement over time.

## 2.3 Number of attempts

Observation of three attempts of wrist and hand movement in action may be required to make a classification. If there is variation in the different attempts of movement, classification is based upon the most consistent movement described during the three attempts.

## 2.4 Classification for young children

For young children observation of the wrist and hand movement in action will be elicited through play. If the young child is not cooperating, consider slowly demonstrating the action that you want the child to complete, engage the child in a game or ask the parent to demonstrate the action. The non-involved upper limb may need to be gently restrained to encourage movement of the limb for classification.

## 2.5 Clients with limited or no active movement

If the client is unable to approach, grasp or release the object on the table, the therapist must create a situation where attempted action of wrist and hand movement can be elicited and observed. This may be achieved by asking a parent or carer to present the object to the child. Observe any attempts of active movement noting the position of the wrist to determine classification level. If there is no active wrist or finger movement, the client will be classified as an E2 or F5 depending on whether the wrist is in an extended or flexed position.



### 3. Set up

#### 3.1 Position of client



Figure 2: Position of client sitting at table for classification of right side



Figure 3: Position of client in supported seating system for classification of left side

The client is seated in a chair at a table (see Figure 2). The size of the chair must be such as to allow the client to have their feet on the floor and their bottom at the back of the chair. The table top should be approximately at waist height. If the client is not able to sit independently without support they can remain in a supported seating system (see Figure 3); sit with support from a therapist or carer; or where appropriate sit on the lap of their parent or carer.

#### 3.2 Objects to elicit wrist and hand movement

It is essential that objects of an appropriate shape and size are used to elicit movement of the wrist, fingers and thumb. The object should be spherical in shape and approximately the size of the client's fist. Examples of objects (an apple and a ball) used to elicit wrist and hand movement are pictured in Figure 4 below.



Figure 4: The use of spherical objects (apple and ball) to elicit wrist and hand movement for classification using the NHDC.





### 3.3 Position of object

The object is placed at a forearm's distance from the edge of the table in the midline in front of the client. A "forearm's distance" is the distance from the client's elbow to wrist crease. The position of the object is important to avoid excessive reach. If the object is too far away, movement of the shoulder, elbow and forearm can compensate for a lack of wrist and finger motion.

If the client is in a supported seating system with a tray, the object can be placed on the tray (see Figure 3). If the client is sitting with support from a therapist or carer the object should be placed on a stable surface in front of them.

### 3.4 Position of camera

If the client's wrist and hand movement is to be videorecorded, the camera is placed one metre from the non-classified side of the client. The camera height should be level with table surface height. The camera zoom is used to focus on the wrist and hand. The wrist and thumb must be visible to capture the wrist and hand movement in action (see Figure 5).

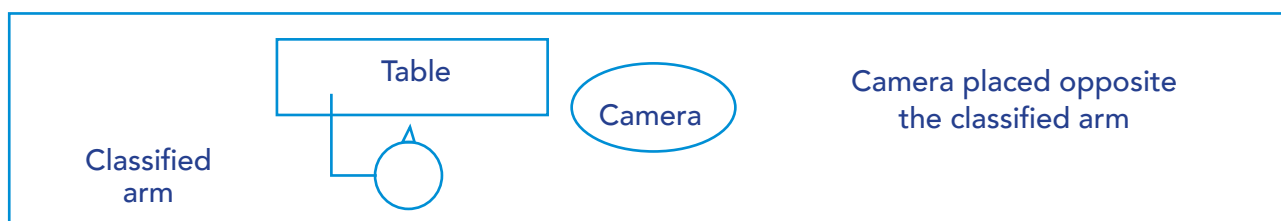


Figure 5: Position of camera (classifying left hand deformity)

### 3.5 Instructions

Once the client and camera are correctly positioned, place the object in front of the client. Ask the client to start with their hand on the edge of the table/tray in front of them before asking them to pick up and put the object down. This action may be repeated three times so that a consistent classification of hand deformity can be made. It is appropriate to explain to the client that you are only observing how the client's wrist and hand muscles work together, not how successful they are in grasping and releasing the object.

### 3.6 Important points to remember

- It is the observation of wrist and hand movement in action that is important.
- Objects are used to elicit movement.
- Objects, as pictured in Figure 4, may be substituted with similar objects provided the objects used do elicit the movement required to classify hand deformity.
- An extended or flexed wrist position is taken from the neutral wrist position of 0°, as pictured in Figure 1.
- The success or type of grip observed is not relevant for classification.



## 4. Determining classification level

The following observations of the client's wrist and hand movement guide classification and help differentiate between levels:

### 4.1 Wrist movement

- Is active wrist movement present?
- Is passive wrist movement present?
  - Is movement into wrist extension achieved through force of the hand on the object?
  - Is movement into wrist extension driven by tight finger flexors when grasping/attempting to grasp the object?

### 4.2 Wrist position

- Does the wrist flex past neutral (0°)?
- What is the wrist position during finger movement?
- Is the maximal degree of wrist flexion greater than 20°?
- Does the wrist remain in a static position of flexion or extension?

### 4.3 Finger movement

- Is there active finger flexion and extension?

Once the movements have been observed the hand deformity classification can be determined and documented. Figure 6, 'Wrist and finger movement considerations of the NHDC' decision tree in Section 5 is designed to guide hand deformity classification. Figure 7, 'Distinction between classification levels' in Section 6 is designed to help observers understand how to differentiate between the categories of the classification.

If there is a variation of wrist position during observation of the client's movement, *the maximum degree of wrist flexion observed at any stage of the movement determines the classification.*



## 5. Wrist and finger movement considerations of the NHDC

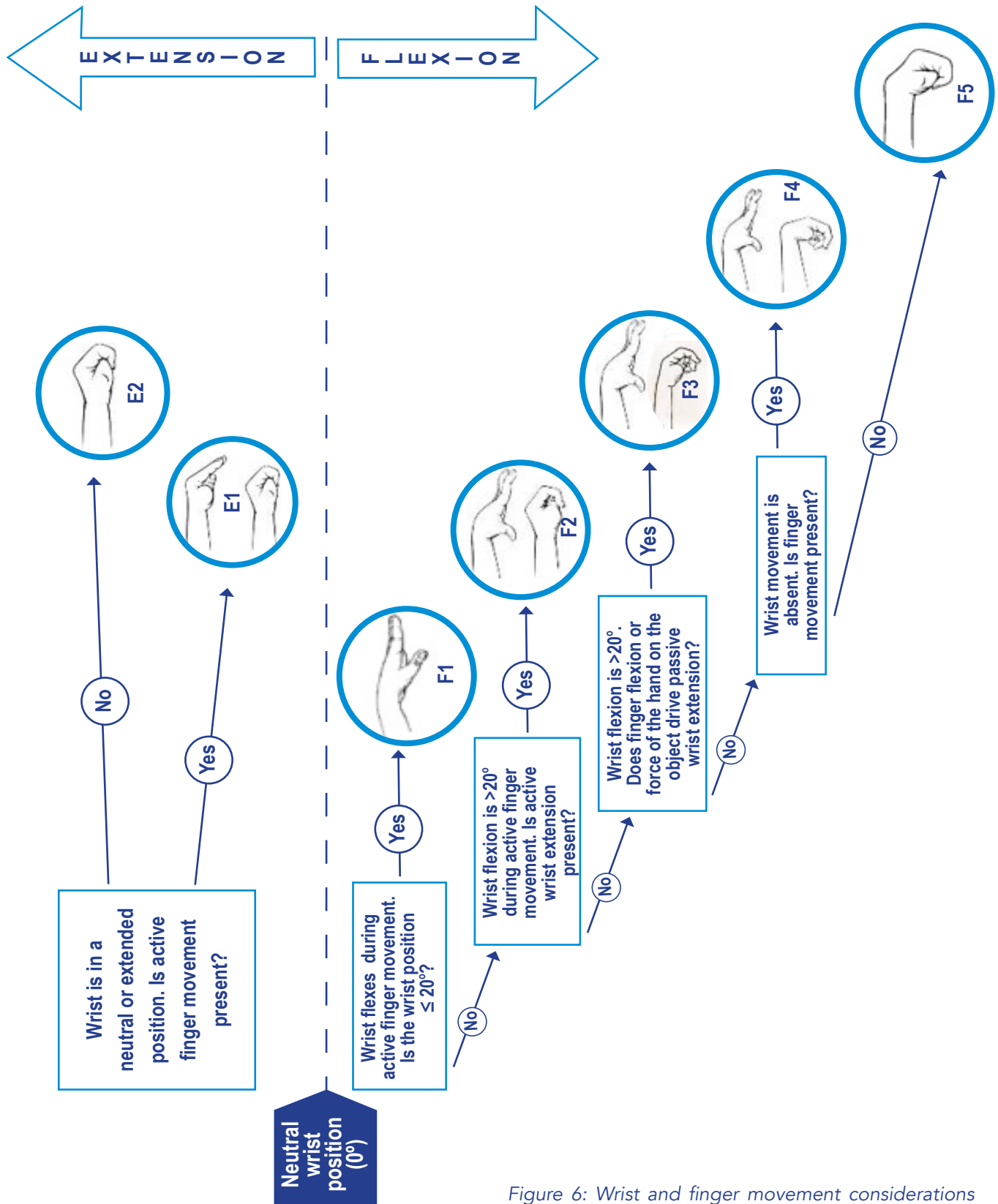


Figure 6: Wrist and finger movement considerations of the NHDC



## 6. Distinction between classification levels

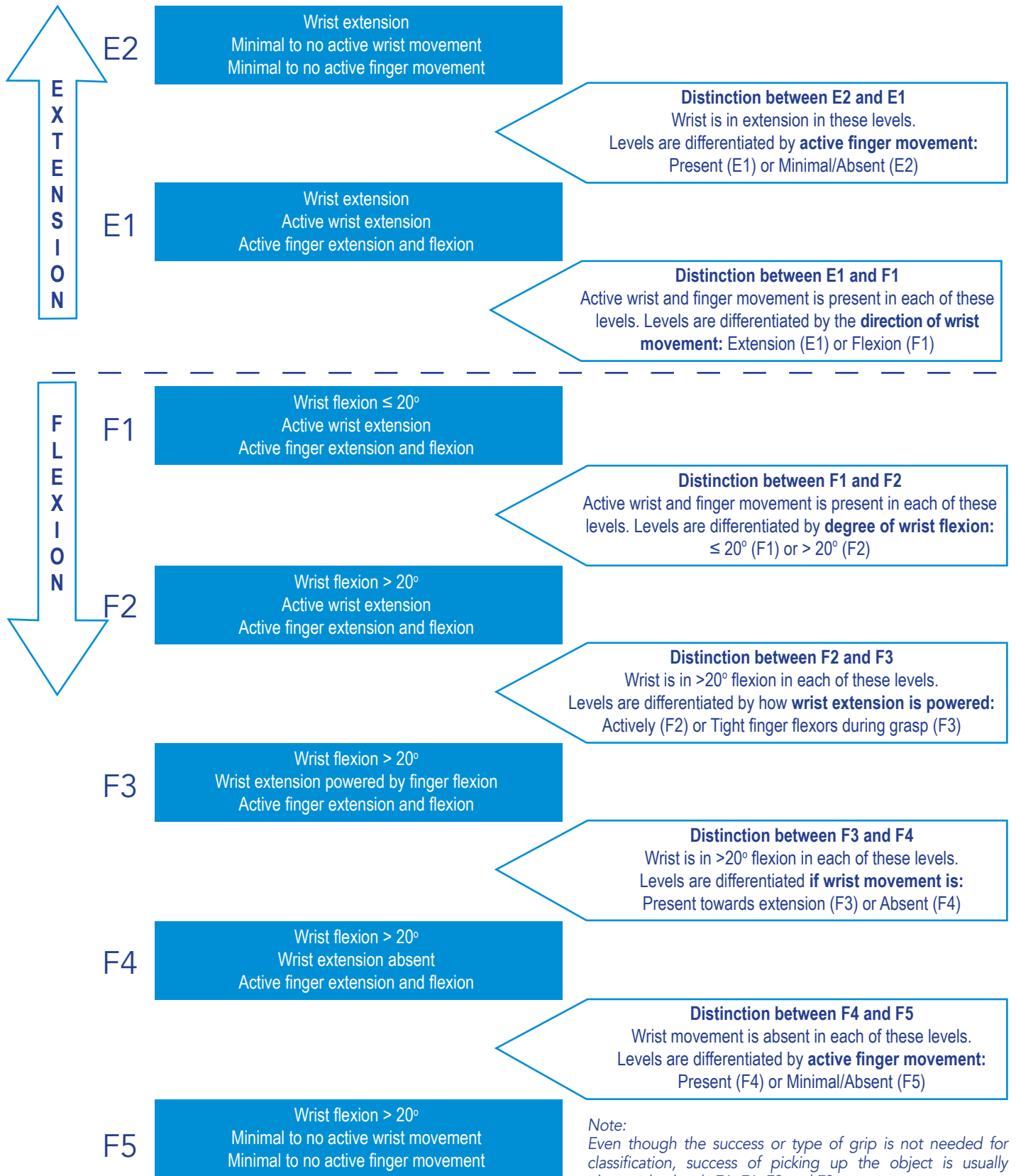


Figure 7: Distinction between NHDC classification levels

The object is usually presented to the client in levels E2 and F5.





## 7. Clinical reporting

Having observed the client's movement, a classification level (e.g. F2, F4 or E1) is recorded. The following are **examples** of how this information may be documented as part of a comprehensive report or communicated to relevant people involved in the client's care.

### F2 classification:

The NHDC was used to classify (client's name) left hand deformity at an F2 level. (Client's name) remained in wrist flexion during the approach, grasp and release of objects and released objects to the table top with his/her wrist position flexed at 45°. During the observed movement (client's name) demonstrated active wrist and finger extension on approach to the object.

### F4 classification:

The NHDC was used to classify (client's name) right hand deformity at an F4 level. Objects were presented to (client's name) while seated in their supported seating system, which included a tray. On presentation of each object (client's name) extended his/her fingers in an attempt to grasp the object. His/her wrist remained at 70° of wrist flexion. No active wrist extension or passive movement driving wrist extension was observed. See the clinical example of a client classified with an NHDC level of F4 in section 11.1. In this case the information was used to prescribe an orthotic intervention as illustrated.

### E1 classification:

The NHDC was used to classify (client's name) right hand deformity at an E1 level. (Client's name) approached the object with their wrist in extension. Active finger flexion and extension was observed but the wrist remained in extension during grasp and release of the object.

This structure can be followed for other levels of the classification.

#### This information will be useful to:

- Report the client's wrist and hand movement in action during a task;
- Maintain a record of the client's wrist and hand movement in action over time in a consistent format;
- Use the reported information for comparison with information gained from future use of the NHDC; and
- Prompt the clinician to consider intervention strategies to match the client's current level of active movement, for example if the client is classified with an NHDC F1 level, bimanual therapy or goal directed training may be an appropriate intervention to consider.



## 8. Clinical application

The NHDC is designed to guide consideration of the structures involved and enhance clinical decision making in the management of hand deformity. **The NHDC should not be used in isolation to determine intervention for a client with neurologically-based upper limb impairment.** Table 1, "The Neurological Hand Deformity Classification" (Section 9) outlines the structural and functional movement impairments associated with hand deformity. Identification of the dominant muscles and forces driving the pattern of deformity are considered and can be used to guide further clinical assessment and clinical intervention decision making. A comprehensive assessment is essential when considering any upper limb intervention. Assessment of upper limb impairment should include observation of posture and movement patterns and measurement of passive and active range of motion (Wilton, 2013).



## 9. The Neurological Hand Deformity Classification (Wilton, 2013)






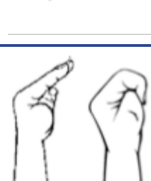

Type	F1. Wrist flexion ≤ 20°, thumb adduction	F2. Wrist flexion > 20°, active wrist & finger extension	F3. Wrist flexion > 20°, wrist extension powered by finger flexors and extensors	F4. Wrist flexion ≤ 20°, active finger flexion & extension, wrist extension absent	F5. Wrist flexion finger flexion, minimal active movement	E1. Wrist extension, finger movement powered by intrinsic muscle action	E2. Wrist extension, finger flexion, minimal active movement
							
<b>Associated thumb deformity</b>	Not always present CMC Adduction	CMC adduction MCP extension IP hyper extension	CMC adduction MCP & IP vary	CMC adduction MCP & IP vary	CMC adduction MCP & IP flexion	CMC adduction MCP flexion IP neutral	CMC adduction, MCP & IP flexion
<b>Associated finger patterns</b>	Hyper extension of PIP joints	Hyper extension of PIP joints	Hyper extension of PIP joints	Hyper extension of PIP joints	Flexion of IP joints	MCP flexion IP extension	Flexion, adduction at MCP joints, flexion of IPs associated with wrist extension posture
<b>Primary location of spasticity</b>	FCU AP	FDP & FDS AP, 1st DI	FCU, FCR, PL FDP & FDS AP	FCU, FCR, PL FDP & FDS AP	Combined spasticity extrinsic & intrinsic musculature of the fingers and thumb	ECRL & ECRB, ECU contributes to ulnar deviation, interossei, AP, FPB	Combined spasticity extrinsic & intrinsic musculature of the fingers and thumb
<b>Muscles not effected by spasticity</b>	Wrist extensors Extrinsic & intrinsic finger flexors & extensors	Wrist & thumb extensors Intrinsic finger musculature	Intrinsic finger musculature	Intrinsic finger musculature	Wrist musculature opposite to wrist position	FDP & FDS	Wrist flexor musculature opposite to wrist position
<b>Contracture</b>	Thumb web space	FDP & FDS end range extension Thumb web space	FCU, FCR limiting end range wrist extension combined with loss of end range FDS & FDP. Thumb web space.	FCU, FCR, PL, FDP, FDS limiting end range extension, Thumb web space	Severe deformity in wrist, fingers & thumb muscles with deficits in volar skin & soft tissue	Intrinsic finger flexors, thumb, palmar skin & fascial shortening. Hand hygiene critical	Wrist extensors & dorsal wrist capsule. Palmar skin & fascial contracture potential severe deformity of wrist, fingers MCP joints & thumb.
<b>Functional deficit</b>	Nil Limited thumb abduction compromising thumb span to clear object for grasp	Palm orientation in grasp, wrist control during finger flexion Thumb disadvantaged effective opposition	Reach and grasp compromised by wrist extension powered by active finger extension or reversed tenodesis action	Approach & grasp compromised by wrist position	No Function	Opening fingers & thumb for grasp disadvantaged by wrist extension - finger flexion/extension possible if wrist in neutral & thumb abducted	No Function

Table 1: The Neurological Hand Deformity Classification



## 10. Orthotic intervention considering hand deformity classification

Once the primary structures causing hand deformity have been identified, therapists need to determine the course of intervention/s, with orthotic intervention being only one potential option. It is essential that orthotic intervention includes clear understanding and description of the primary purpose of the orthosis (Garbellini, Robert, Randall, Elliott, & Imms, 2017).

**The primary purpose of orthoses are outlined in Table 2 below.**

Primary purpose of orthosis	Definition
Immobilisation	Stop motion at a specific joint
Mobilisation	Apply forces to gain motion, either passively or as a dynamic movement assist
Restrictive	Prevent motion in one direction at a specific joint, while allowing motion in another direction
Torque transmission	Transfer movement torque created in one joint to another proximal or distal

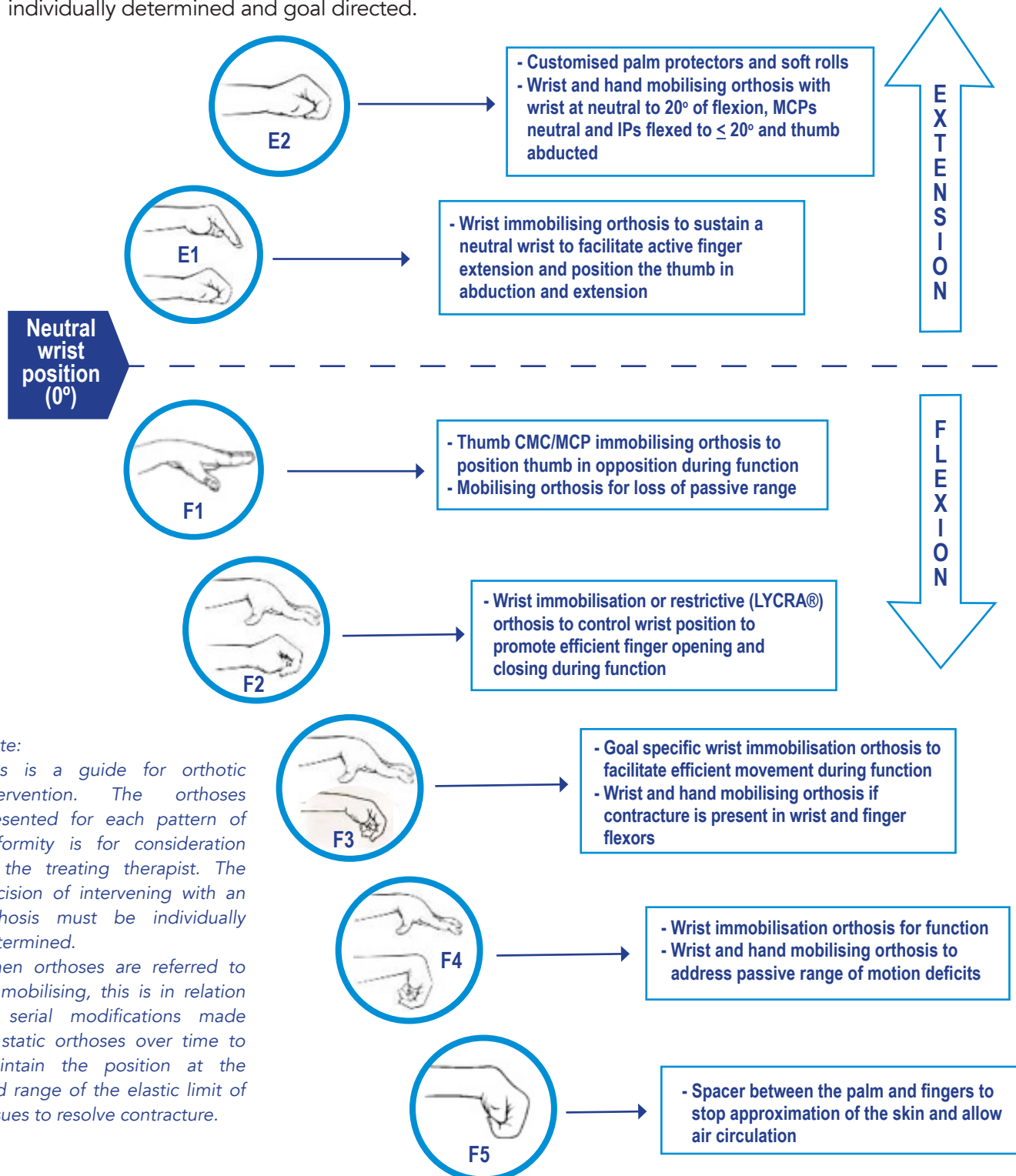
Table 2: Primary purpose of orthoses, as derived from Australian Hand Therapy Association (2012); Colditz (1996); Fess (2011); American Society of Hand Therapists (1992).





## 11. Orthosis considerations utilising the NHDC

Figure 8 identifies orthoses that may be considered for each pattern of hand deformity and is provided as a tool to facilitate therapists' clinical decision making. It is essential that the choice of orthosis is individually determined and goal directed.



**Note:**

This is a guide for orthotic intervention. The orthoses presented for each pattern of deformity is for consideration of the treating therapist. The decision of intervening with an orthosis must be individually determined.

When orthoses are referred to as mobilising, this is in relation to serial modifications made to static orthoses over time to maintain the position at the end range of the elastic limit of tissues to resolve contracture.

Figure 8: Orthosis considerations using the NHDC



## 11.1 Clinical example

A client with an NHDC of F4 is portrayed in Figure 9 below. The client presented with a flexed wrist posture greater than 20° and active finger flexion. Active wrist and finger extension were absent. Comparison of previous clinical examination identified increasing loss of the client's composite passive wrist and finger extension.



Figure 9: F4 classification

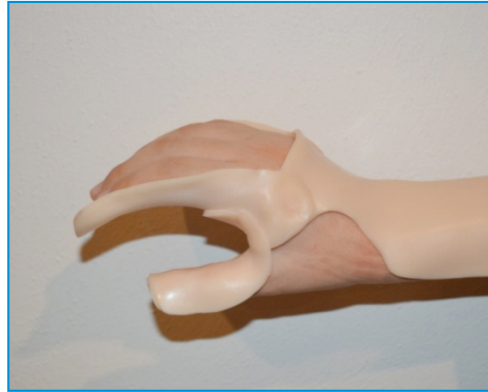

Figure 10: Wrist and hand orthosis

The dorsal/volar wrist and hand mobilising orthosis, as pictured for the same client in Figure 10, is designed to address passive range of motion deficit and is worn at night to provide a low load, long duration stretch to flexor compartment musculature. The orthosis can be serially adjusted over time to accommodate any changes in range of motion. After consistent night wear, for at least 6-8 hours in duration a day and a period of three months, it would be anticipated that the client's passive range of motion would be greater than when orthosis wear commenced.

## 12. Conclusion

The NHDC is intended to:

- Categorise wrist and hand movement in action;
- Assist identification of structures driving hand deformity;
- Guide clinical assessment; and
- Enhance clinical decision making regarding the use of upper limb orthoses as part of the overall management of upper limb impairment.



## 13. Authors

**Simon Garbellini** MHIthServMgt, BSc (OT), PhD candidate

Simon has been working as an occupational therapist for more than 20 years. He is currently a Senior Occupational Therapist for the Cerebral Palsy Mobility Service within the Department of Paediatric Rehabilitation at Perth Children's Hospital. He runs a private practice with a focus on management of neurological upper limb impairment.

Simon is an associate investigator within two multicentre randomised controlled trials, at Australian Catholic University (ACU), investigating the medium to long-term use of rigid wrist and hand orthoses for children with cerebral palsy. Simon is completing a PhD at ACU that is embedded within the trials to investigate clinical decision-making about upper limb orthosis prescription for children with cerebral palsy, and use of the Neurological Hand Deformity Classification (NHDC) as a tool to guide orthotic prescription. Simon is a member of the Australian Hand Therapy Association (AHTA) and Australasian Academy of Cerebral Palsy and Developmental Medicine (AusACPDM).

**Judith Wilton** MSc, PGradDipHthSc, BAppSc (OT)

Judith has worked in upper limb rehabilitation as a clinical practitioner and academic since graduating as an occupational therapist over 35 years ago. She has worked in hand therapy private practice, and consulted to numerous organisations providing services to clients with neurological impairment.

Judith was a member of faculty of Curtin University's School of Occupational Therapy for over 20 years teaching undergraduate and postgraduate courses. She established the first Australian university-based hand and upper limb rehabilitation graduate programme for occupational therapists and physiotherapists. She has published numerous journal articles and presented courses and workshops on hand therapy and orthotic fabrication across Australia and internationally.

Judith is an active member of the AHTA, and has held numerous executive committee positions including National President. She is responsible for the development and continued presentation of courses on Hand and Upper Limb Orthotic Fabrication conducted by the AHTA across Australia. She was awarded life membership of the AHTA in 2002.

## 14. Correspondence

Simon Garbellini, E-mail: [simon.garbellini@health.wa.gov.au](mailto:simon.garbellini@health.wa.gov.au)

## 15. Acknowledgment

We acknowledge the generous contribution of the clients and families who have given permission for their photographs to be used in this manual. Thank you to Professor Peter Rosenbaum, Professor Christine Imms, Dr Melinda Randall and Professor Catherine Elliott for their tireless review and assistance in the development of this manual. Thank you to Telethon for providing funding assistance for this project.



## 16. References

- American Society of Hand Therapists. (1992). *Splint Classification System*. Online: American Society of Hand Therapists.
- Australian Hand Therapy Association. (2012). *Australian Hand Therapy Association Hand and Upper Limb Orthosis/Splint schedule*. Online.
- Colditz, J. C. (1996). Principles of splinting and splint prescription. In C. A. Peimer (Ed.), *Surgery of the Hand and Upper Extremity* (pp. 2389-2410). New York: McGraw-Hill, Health Professions Division.
- Fess, E. E. (2011). Orthoses for mobilization of joints: principles and methods. In T. M. Skirven, A. L. Osterman, J. Fedorczyk, & P. C. Amadio (Eds.), *Rehabilitation of the hand and upper extremity : expert consult* (pp. 1588-1598). Philadelphia: Elsevier Health Sciences.
- Garbellini, S., Robert, Y., Randall, M., Elliott, C., & Imms, C. (2017). Rationale for prescription, and effectiveness of, upper limb orthotic intervention for children with cerebral palsy: a systematic review. *Disability and Rehabilitation*, 1-11. doi:10.1080/09638288.2017.1297498
- Georgiades, M., Elliott, C., Wilton, J., Blair, E., Blackmore, M., & Garbellini, S. (2014). The Neurological Hand Deformity Classification for children with cerebral palsy. *Australian Occupational Therapy Journal*, 61, 394-402. doi:10.1111/1440-1630.12150
- House, J., Gwathmey, F., & Fidler, M. (1981). A dynamic approach to the thumb-in palm deformity in cerebral palsy. *J Bone Joint Surg Am*, 63(2), 216-225.
- Kirshner, B., & Guyatt, G. (1985). A methodological framework for assessing health indices. *Journal of chronic diseases*, 38(1), 27-36.
- Klingels, K., De Cock, P., Molenaers, G., Desloovere, K., Huenaearts, C., Jaspers, E., & Feys, H. (2010). Upper limb motor and sensory impairments in children with hemiplegic cerebral palsy. Can they be measured reliably? *Disability & Rehabilitation*, 32(5), 409-416.
- McConnell, K., Johnston, L., & Kerr, C. (2011). Upper limb function and deformity in cerebral palsy: a review of classification systems. *Developmental Medicine & Child Neurology*, 53(9), 799-805. doi:10.1111/j.1469-8749.2011.03953.x
- Portney, L., & Watkins, M. (2015). *Foundations of clinical research : applications to practice* (3rd Edition. ed.): Philadelphia, PA : F.A. Davis Company.
- Rosenbaum, P., Eliasson, A.-C., Hidecker, M. J. C., & Palisano, R. J. (2014). Classification in Childhood Disability: Focusing on Function in the 21st Century. *Journal of Child Neurology*, 29(8), 1036-1045. doi:10.1177/0883073814533008
- Rosenbaum, P., Russell, D. J., Cadman, D. T., Gowland, C., Jarvis, S., & Hardy, S. (1990). Issues in Measuring Change in Motor Function in Children with Cerebral Palsy: A Special Communication. *Physical Therapy*, 70(2), 125-131.
- Tonkin, M. A., Freitas, A., Koman, A., Leclercq, C., & Van Heest, A. (2008). The surgical management of thumb deformity in cerebral palsy. *J Hand Surg Eur Vol*, 33(1), 77-80. doi:10.1177/1753193407087891
- Tonkin, M. A., Hatrick, N. C., Eckersley, J. R., & Couzens, G. (2001). Surgery for cerebral palsy part 3: classification and operative procedures for thumb deformity. *J Hand Surg Br*, 26(5), 465-470. doi:10.1054/jhsb.2001.0601
- Wilton, J. (2003). Casting, splinting, and physical and occupational therapy of hand deformity and dysfunction in cerebral palsy. *Hand clinics*, 19(4), 573-584.
- Wilton, J. (2013). *Orthotic intervention and casting in the presence of neurological dysfunction Hand Splinting Orthotic Intervention: Principles of design and fabrication* (2nd ed., pp. 195-235). Western Australia: Vivid Publishing.
- World Health Organization. (2001). *International Classification of Functioning, Disability and Health*. Geneva: World Health Organization, 1-303.
- Zancolli, E. A. (2003). Surgical management of the hand in infantile spastic hemiplegia. *Hand clinics*, 19(4), 609-629.
- Zancolli, E. A., & Boyes, J. H. (1979). *Structural and dynamic bases of hand surgery*. Philadelphia: J.B. Lippincott.
- Zancolli, E. A., Goldner, L., & Swanson, A. (1983). Surgery of the spastic hand in cerebral palsy: Report of the Committee on Spastic Hand Evaluation. *J Hand Surg*, 8(5.2), 776 - 772.
- Zancolli, E. A., & Zancolli, E. R. (1981). Surgical management of the hemiplegic spastic hand in cerebral palsy. *The Surgical clinics of North America*, 61(2), 395-406.
- Zancolli, E. A., & Zancolli, E. R. (1984). The infantile spastic hand surgical indications and management. *Annales de Chirurgie de la Main*, 3(1), 66-75. doi:http://dx.doi.org/10.1016/S0753-9053(84)80064-2
- Zancolli, E. A., & Zancolli, E. R. (1987). Surgical rehabilitation of the spastic upper limb in cerebral palsy. In D. W. Lamb (Ed.), *The Paralysed Hand*. Edinburgh [Lothian]; New York: Churchill Livingstone.ww